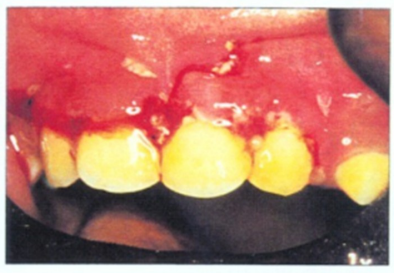

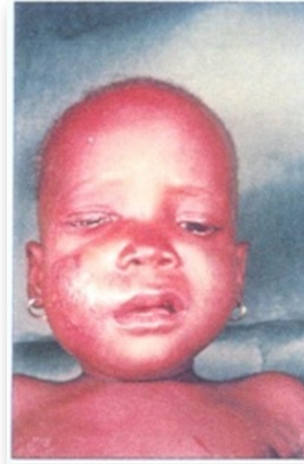
The Clinical Stages of Noma

Stage 1



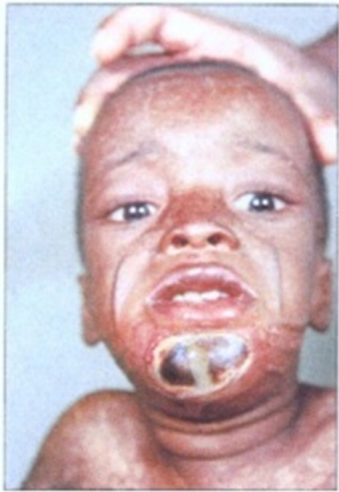The overall consensus is that the initial phase is Acute Necrotizing Gingivitis (ANG) which under circumstances still to be elucidated may evolve into the gangrenous phase. Today scientists are more inclined to say that any intra-oral lesion can play the role of an entry point to the disease.

Stage 2



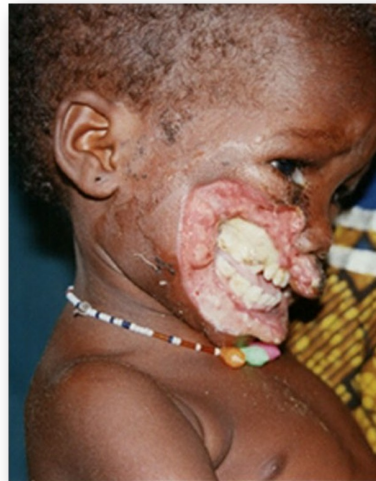If the immune system is sufficiently weakened the soft tissue against the gingival lesions start swelling.

Stage 3



In a few days, in the absence of any intervention, there is formation of a gangrenous plaque which indicates the area of future loss of tissue.

Stage 4



On healing, large amounts of scar tissue prevent anymore than minimal opening of the mouth and the functional as well as aesthetic sequelae are extremely distressing.